

SHORT REPORT

**MAIN RESULTS OF THE STUDING OF PATHOLOGIES IN THE  
SKULL OF HEDGEHOGS (ERINACEIDAE, LIPOTYPHLA)  
LIVING ON THE TERRITORY OF BELARUS**

**A.A. Savarin<sup>1</sup>, V.A. Savarina<sup>2</sup>**

<sup>1</sup>Francysk Skaryna Gomel State University, Gomel, Republic of Belarus

<sup>2</sup>Gomel State Medical University, Gomel, Republic of Belarus

**Abstract.** Analysis of pathomorphological changes in the skulls of hedgehogs living on the territory of Belarus was carried out. The primary purpose of research was to evaluate the effect of identified abnormalities on the viability of individuals and hedgehog populations at all. Swelling of the frontal bone with thinning of adjacent areas and calcium salts deposition in the foramen magnum are the most common pathologies of the cranial region. Increased occurrence frequency of pathologies of the cranial region during individuals growing up proves chronic pathophysiological processes. These processes in the skull and the central nervous system increase mortality of individuals and lead to a significant rejuvenation of populations (age groups Ad-1 and Ad-2 are predominating).

**Keywords:** *Erinaceus concolor roumanicus*, skull, pathologies, pathogenic factors.

**Corresponding Author:** Alexander Savarin, Francysk Skaryna Gomel State University, 104 Sovetskaya str., Gomel 246019, Republic of Belarus, e-mail: [a\\_savarin@mail.ru](mailto:a_savarin@mail.ru)

**Manuscript received:** 13 February 2017

## 1. Introduction

The northern white-breasted hedgehog (*Erinaceus concolor roumanicus* Barrett-Hamilton, 1900) is the only member of the family Erinaceidae on the territory of Belarus. The white-breasted hedgehog is a common species in different types of forests, shelterbelts and agrocenoses.

The authors hold the idea of subspecies status of «roumanicus» group [3].

In the course of many years of research (1995-2010) the next facts were revealed: anomalous behavior of hedgehogs and the low life expectancy of individuals, usually up to 3 years (which is significantly lower than in Europe [1]), as well as the population prevalence of hedgehogs have hibernated only once. These circumstances suggested the impact of powerful pathogenic factors, which not only impair the central nervous system, but also increase significantly the individuals' mortality. Therefore, the main purpose was to analyze pathomorphological changes in the skulls of hedgehogs and to estimate their impact on the viability of individuals and the population on the whole. Understanding the etiology of these changes is of both theoretical and practical importance: pathophysiological processes can transform many population

characteristics (age structure, the age of mating, morphometric characteristics, and others).

## 2. Materials and methods

The cranial features of individuals ( $n > 400$ ) captured on the territory of all regions of Belarus were analyzed. Age of animals was identified by a complex of signs: the date of capture, size, weight and color of the needles, the degree of grinding of the teeth, skull ossification and its measurements, the development of reproductive organs. The following age groups were picked up: subadultus – yearlings (immature individuals), adultus – 1-2-year-old sexually matured individuals, adultus – 2-3-year-old sexually matured individuals, senex – old individuals (do not participate in reproduction).

## 3. Results and their discussion

I. The most common pathologies of the brain skull were:

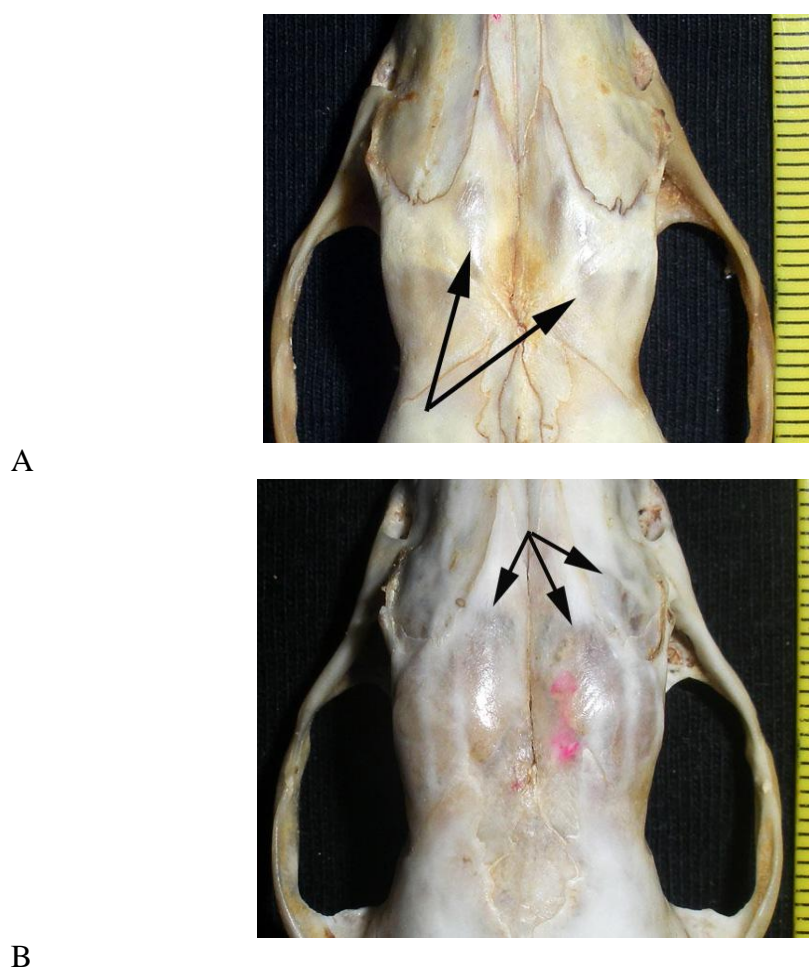
- swelling of the frontal bone with thinning of adjacent areas (in 60 % of adult individuals, in 10 % of yearlings (Figure 1);
- calcium salts deposition in the foramen magnum (70 % и 10 % accordingly) (Figure 2);
- presence of areas with no bone tissue in the bregma (adults only, about 13%);
- swelling and the divergence of the skull sutures (only in adults, about 5%).

The increase in the incidence of abnormalities in the brain skull during individuals growing up indicates chronic course of pathophysiological processes in the neurocranium causing intracranial hypertension. Revealed morphological and anatomical features of the outer and inner sides of the calvaria physiologically correspond to each other; they are adaptive changes aimed at reducing the intracranial pressure and the preservation of bone mobility.

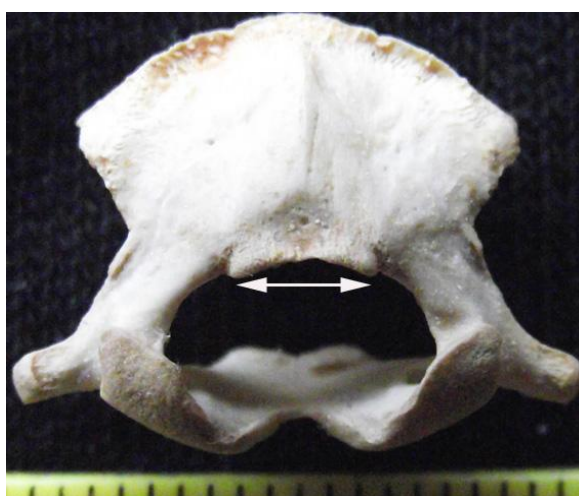Features of formation and variability of bregmatic bones in the postnatal period (two types of its formation, the high incidence of multiple forms in yearlings and adults, large bone size, elongation of its teeth, and others.) prove chronic pathophysiological processes in the CNS. The frequency of this epactal bone can't be considered as a diagnostic sign in defining of the various taxa of Erinaceidae family.

II. Pathologies in the upper jaw are more various than in the lower one. One reason for this is the impact of additional pathogens that cause inflammation in the CNS, and lead to pathological deformations of the brain skull.

Destruction of premaxilla starting with its swelling has oncological origin. The destruction of the bone tissue at the base of the preorbital foramen is a jawbone cyst. Osteoporosis of the jaw bone, exostoses on the angular process, calcination of intracranial foramina and foramen magnum confirm the view of the systemic impairments of calcium metabolism.



**Fig. 1.** Swelling of the frontal bone with thinning of adjacent areas:  
A – low degree, B – high degree



**Fig. 2.** Deposition of calcium salts in the foramen magnum

III. Intensification of the pathophysiological processes in the skulls of hedgehogs results in significant mortality of individuals and rejuvenation of the population (age groups Ad-1 and Ad-2 are predominating). Many pathophysiological processes (oncological, inflammatory, large exostosis formation) cause pain in animals that leads to anomalous behavior and profound neurological impairments up to coma.

IV. The most important factors impacting on pathophysiological processes intensification in the hedgehogs skulls are:

– adverse changes in wintering conditions in recent decades (long period without snow, thaw, rains) leading to hypothermia of individuals and reducing in their immunity;

– increase in ectoparasites infection (especially Exodes). Tick-borne encephalitis and Lyme disease affects the CNS by causing chronic inflammatory processes.

#### **4. Conclusion**

Revealed neurocranium changes are reliable signs of pathophysiological processes in the CNS. It points to the relevance and medical-epidemiological appropriateness of microbiological and virological investigations of the hedgehogs (living on the territory of Belarus) hadn't been carried out before. To achieve the objectives the cooperation of different profiles specialists is required.

Future studies should clarify the etiology of pathophysiological processes by different methods: the study of bone cuts, analysis of the chemical composition of cerebrospinal fluid and blood.

#### **References**

1. Heddergott M., Steinbach O., Heddergott C., (2010) Zur Alterstruktur des Braunbrustigels *Erinaceus europaeus* (Linnaeus, 1758) im Stadtgebiet Heilbad Heiligenstadt (Thüringen) (Mammalia: Insectivora, Erinaceidae), *Mauritiana (Altenberg)*, 21, 231-239.
2. Savarin A.A., (2015) The skull pathologies of northern white-breasted hedgehog (*Erinaceus concolor roumanicus*) living on the territory of Belarus, Gomel, BelGUT, 190 p. (in Russian).
3. Zaitsev M.V., Voita L.L., Sheftel B.I., (2014) The mammals of Russia and adjacent territories, Lipotyphlans, Saint Petersburg, ZIN Russian Academy of Sciences, 383p. (in Russian).